

THE MANAGEMENT OF A DEHISCED SURGICAL WOUND IN A BARIATRIC PAEDIATRIC PATIENT - THE USE OF FLAMINAL® AND V.A.C THERAPY

CAROL JOHNSON¹, SHARON WILSON²

¹CLINICAL MATRON—TISSUE VIABILITY, COUNTY DURHAM & DARLINGTON NHS FOUNDATION TRUST, DARLINGTON MEMORIAL HOSPITAL, HOLLYHURST ROAD, DARLINGTON, CO DURHAM, DL3 6HX. carol.johnson@cddft.nhs.uk

²SENIOR TISSUE VIABILITY NURSE, COUNTY DURHAM & DARLINGTON NHS FOUNDATION TRUST, DARLINGTON MEMORIAL HOSPITAL, HOLLYHURST ROAD, CO DURHAM, DL3 6HX

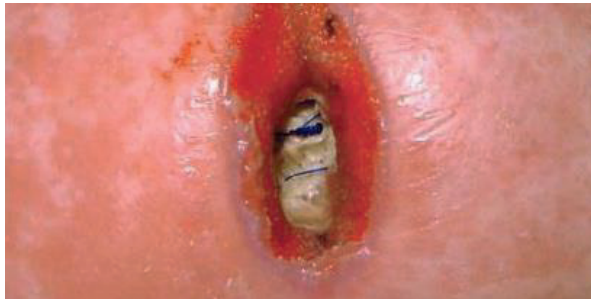Introduction

Flaminal® is a hydro-active alginate gel dressing with an antimicrobial enzyme system. Flaminal® supports the healing of a wound, has an antimicrobial action, is safe to skin cells, is hypoallergenic, and maintains a moist wound environment and continuously debrides the wound. Vacuum assisted closure (V.A.C) is a non invasive, dynamic therapy which helps promote wound healing through the application of negative pressure to the wound site.

Method

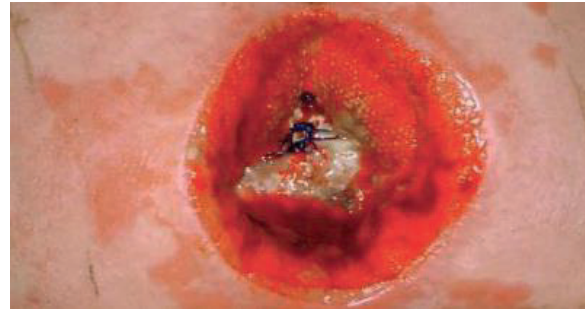
Child B, a 10 year old obese child who was normally in good health, presented with acute perforated appendicitis requiring an emergency laparotomy and removal of appendix. Deep tension sutures and skin clips were used to close the wound. Following an initial post operative period in ITU recovery was uneventful, leading to transfer back to the paediatric unit.

Figure 1.



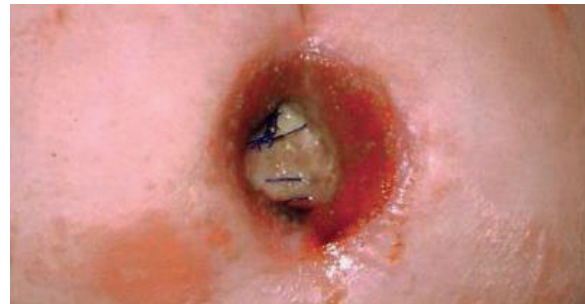Skin sutures were removed on day 7 (Figure 1) and deep tension sutures on day 10. It was noted, on day 10, that the surgical incision had dehiscenced to sub-wound which was intact (Figure 2). Advice was sought from the tissue viability team. Upon assessment the wound was deemed a surgical wound which had dehiscenced following removal of sutures and clips. There was evidence of slough at the base of the wound and there was localised erythema to the surrounding skin. The wound measured 9cm x 3cm and 3cm in depth, Child B was aphyrexial and displayed no clinical signs of acute infection. The aim was to debride the slough and promote granulation. Child B was found to have a very unbalanced diet consisting of very limited portions of protein, high portions of carbohydrates and high fat content. A referral was made to the paediatric dietician in order to provide nutritional advice to Child B and his mother.

Figure 2.



Oral antibiotics were prescribed following the results of the wound swab confirming presence of group B streptococcus and conservative hydrogel treatment was used for 10 days with little change to the wound. It was decided that a sharp debridement was necessary to remove the slough from the base of the wound and this was undertaken within the clinical environment. Although the wound was decreasing in size the slough remained at the base of the wound. It was agreed that the wound would benefit from a complete surgical debridement which took place under general anaesthesia shortly afterwards. The wound was essentially clean with a small amount of slough to the base and V.A.C therapy was commenced. Granulation tissue became visible around the wound edges within 2 dressing changes; however the base of the wound resloughed very quickly following the surgical debridement. With the aim of avoiding a further surgical procedure it was decided to use Flaminal® in conjunction with V.A.C therapy with the intention of desloughing the wound and promoting rapid granulation (Figure 3). Flaminal® was applied to the base of the wound followed by Granufoam with a negative pressure of 25mmHg. Dressing changes occurred every 48 hours.

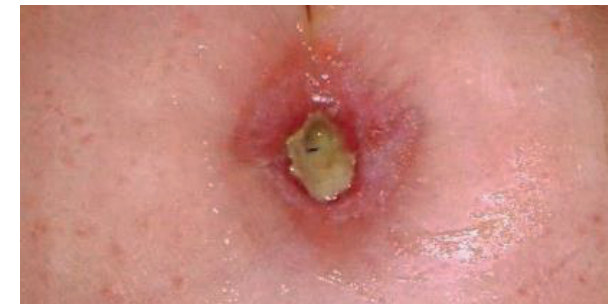
Figure 3.



Results

After a further 3 dressing changes the wound measured 4cm x 4cm x 2.5cm deep. Over the next 5 days (2 dressing changes) the wound continued to make good progress and V.A.C therapy was stopped. Wound management continued with Flaminal® and Allevyn adhesive foam dressing applied on alternate days. Ten days later the wound measurement was 2cm x 2cm x 1.5cm. It was noted that there was a minimal amount of slough present at the base of the wound with granulation buds also visible. Dressings continued until the wound was beginning to epithelialise and wound base was completely debrided of slough (Figure 4). Child B went on to heal completely.

Figure 4.



Discussion

With the rising levels of obesity within the paediatric population whose nutritional deficits are apparent, it is envisaged that there is likely to be a rise in wound complication becoming more probable in this patient group. As tissue viability teams we need to explore advanced treatments and combination therapies in order to deal with the multiple challenges these cases present. The utilisation of advanced therapies and combination with antimicrobial treatments in this instance had the desired results.

Conclusion

Flaminal® in combination with V.A.C therapy facilitated healing in a dehiscenced surgical wound in a bariatric paediatric patient.