

# THE MANAGEMENT OF A PATIENT FOLLOWING ORBITAL EXENTERATION FOR MALIGNANT NEOPLASM

Fiona Cunningham. NHS Scotland (St John's Hospital), Out Patients Department 2, LIVINGSTON, West Lothian, EH54 6PP. fiona.cunningham@nhslothian.scot.nhs.uk

## Introduction

This poster describes the management of Mrs P, an 83-year-old active and independent lady who had undergone orbital exenteration for a malignant neoplasm to her right lower eyelid resulting in an orbital cavity. The most common indication for exenteration surgery is the treatment of epithelial malignancy together with orbital invasion.<sup>1</sup> Exenteration refers to the surgical removal of the eyeball and the surrounding tissues, these including the eyelids (the extent depending on the disease being treated), and the muscles, nerves and fatty tissue adjacent to the eye. At wound review and dressing change on third day post op Mrs P's dressing was saturated. The wound (socket) had a circumference of 3-4cm, with an overall depth of 3cm. The wound bed was 100% sloughy with high levels of exudate causing skin excoriation, discomfort and embarrassment for Mrs P. An important consideration was also risk of increased bioburden. Several dressing regimens were tried which included a silver impregnated hydrofiber for 10 days followed by Fucidin® ointment. Following a course of antibiotics there was a minor reduction in exudate levels but strike through remained an issue.

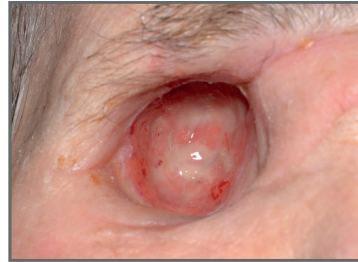


Figure 1

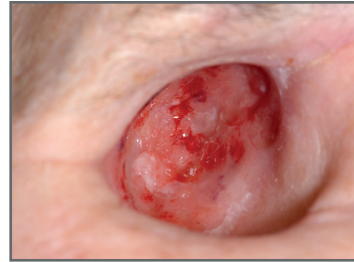

Figure 2

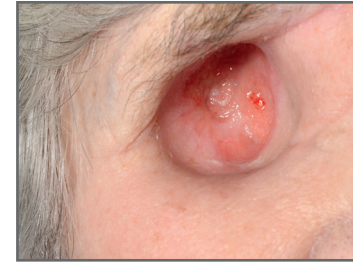

Figure 3

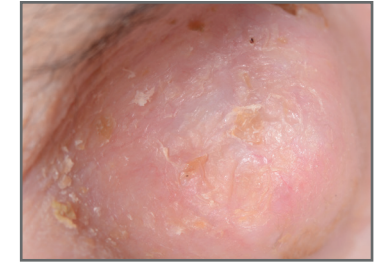

Figure 4

## Method

The aims of treatment were to autolytically debride the sloughy tissue and manage the exudate whilst protecting the surrounding skin. It was also important to improve Mrs P's quality of life as she had stopped socialising with friends and family due to the uncontrolled exudate and leakage.

At 8 weeks post op, Flaminal®, an Enzyme Alginate®, was commenced with twice weekly dressing changes (fig 1). Flaminal® Forte was chosen as it is indicated for moderate to high levels of exudate. Simple gauze, an eye pad and skin tone tape were used as secondary dressings.

## Results

Mrs P tolerated the dressing regimen well and there was a marked improvement within one week with a reduction in slough and the appearance of healthy granulation tissue evident (fig 2). There was also a notable reduction in exudate levels and leakage, which in turn improved Mrs P's self-esteem and she started to socialise again.

By week 11 Mrs P's wound had decreased to 1-2cm with minimal exudate (fig 3) and by week 16 her wound was clean and granulating, measuring <1cm; the wound took a further 3 weeks to heal (fig 4).

One month after healing, Mrs P returned to theatre for minor reconstruction of her eyebrow; unfortunately, there was slight breakdown of the socket wound bed. Flaminal® Forte was recommenced and complete healing was again achieved within 3 weeks supported by strong healthy epithelialised tissue within the eye socket.

## Discussion

Orbital exenteration involves the removal of the entire contents of the orbit and depending on the tumour size and degree of invasion; it may involve radical removal of the contiguous structures. Orbital exenteration is usually undertaken to remove a malignant tumour which involves the eyelids or structures around or behind the eye, and which needs to be removed to prevent local extension and / or metastatic spread. Fifty to sixty per cent of orbital exenterations are performed for tumours in the eyelid or periocular skin which are mostly basal cell carcinomas (BCC) and squamous cell carcinomas (SCC).<sup>2</sup> Orbital exenteration remains an infrequent procedure worldwide.<sup>3</sup>

With the prospect of such a disfiguring and destructive procedure for someone in their 83rd year it was important to ensure that Mrs P's journey through the post-operative healing process was as trauma free as possible. Addressing the issues of concern to Mrs P (namely leakage and exudate), as effectively as possible was paramount to enable her to remain as socially active as quickly as was feasible given the surgery she had undergone. Flaminal was selected to help expedite this process.

Flaminal® (Flen Health) is available in two formulations with high alginate content, which are indicated for the reduction of bacterial growth in wounds. They comprise hydrated alginate polymers in a polyethylene-glycol (PEG) matrix embedded with enzymes glucose oxidase and lactoperoxidase to control bioburden.<sup>4</sup> Flaminal® has the capability to absorb excess exudate whilst remaining in a gelled state, promote debridement and control bioburden.

## Conclusion

Exudate control, autolytic debridement of slough and reduction in bioburden were facilitated by Flaminal® in the management of Mrs P orbital cavity. Flaminal® helped to improve Mrs P's quality of life enabling her to resume activities that were important to her. She is now awaiting the next step in the process, namely 3D scanning and a colour matched prosthetic eye.

### References

1. Guerra AS, Barbosa R, Choupin M et al (2011) Orbital exenteration for eyelid skin carcinoma. *Eur J Plast Surg* 34: 239-243
2. Tyers AG (2006) Orbital exenteration for invasive skin tumours. *Eye* 20: 1165-1170
3. Turkmen A, Temel M, Gokce A, Bekerecioglu M (2013) orbital exenteration for the treatment of advanced periocular skin cancer. *Eur J Plast Surg* 36: 69-74
4. White R (2006) Flaminal: a novel approach to wound bioburden control. *Wounds UK* 2 (3):64-9