

FLAMINAL® FOR THE ONGOING MANAGEMENT OF EXTENSIVE SKIN LESIONS FROM KAPOSI'S SARCOMA

Sharon Gardner, Tissue Viability Nurse. Christie NHS Foundation Trust, 550 Wilmslow Rd, Manchester M20 4BX. sharon.gardner@christie.nhs.uk

Introduction

Whilst Kaposi's sarcoma (KS) is the most common neoplasm for people living with AIDS today, it is nonetheless an unusual vascular tumour.¹ It is not only HIV-positive individuals who present with KS; any immune compromised person infected with KS – associated herpesvirus (KSHV) or human herpesvirus 8 (HHV-8) is at risk.² Despite their environmental and immunological variation, the development of all four epidemiologic forms of KS, namely classic (sporadic), African (endemic), AIDS-associated (epidemic) and immunosuppression (iatrogenic-associated), are dependent largely on infection with KS herpesvirus/human herpesvirus -8 (KSHV/HHV-8). In the UK 94% of KS cases are caused by both HHV-8 and HIV infection, with the remaining 6% caused by HHV-8, with no HIV present.³

This case describes the wound care management of John (pseudonym), a 51-year-old male with Aids-related KS, who was referred to the oncology tissue viability team for assessment and management of chronic, painful, and extensive skin lesions to both his lower limbs; these were having a major impact on his quality of life. John was no longer able to work due to the disease progression and its sequelae necessitating periods of hospital admission and IV antibiotics. He was also finding it difficult to go out due to the uncontrolled pain, exudate and malodour.

Method

John presented with multiple circumferential wounds to his lower legs, feet and toes (fig.1). Many of the wounds were deep with exposed tendon. They were all covered in slough and necrotic tissue and were malodorous with high levels of exudate (fig.2). Previous treatments had included hydrofiber dressings which John found uncomfortable; plus, they did not effectively manage the odour or reduce the wound bioburden. John had endured several episodes of infection including cellulitis.

The primary aims of the tissue viability team were to address John's major symptoms of pain, exudate and malodour, which would subsequently improve his quality of life. If they could remove the devitalised tissue this would help to reduce the wound bioburden, whilst concomitantly controlling the exudate levels alongside the malodour. A new treatment protocol was implemented comprising Flaminal® Hydro and Forte (where exudate levels were high), a superabsorbent pad, secured with orthopaedic wool and a retention bandage. Dressings were initially changed alternate days for the first two weeks, but reduced to every three days. John and his partner were shown how to manage his wounds to enable them to regain some freedom from constant clinic appointments; this also meant that his legs were redressed as deemed necessary by John thus giving him some control over the management of his wounds.

References

1. Antman K, Chang Y (2000) Kaposi's sarcoma. N Engl J Med 342: 1027-1038
2. Schneider JW, Dittmer DP (2017) Diagnosis and treatment of Kaposi's sarcoma. Am J Clin Dermatol 18:529-539
3. <http://www.macmillan.org.uk/information-and-support/kaposi-sarcoma>
4. Emmons KR, Lachman VD. Wound Ostomy Continence Nurs (2010) 37(6): 639-46
5. Holloway S, Bale S, Harding K et al (2002) Evaluating the effectiveness of a dressing for use in malodorous, exuding wounds. Ostomy Wound Manage 48(5):22-8

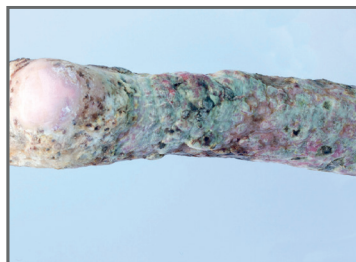


Figure 1

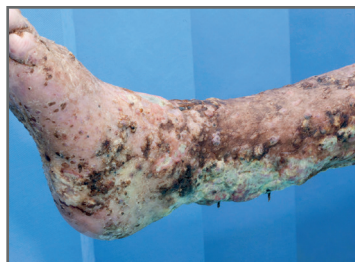

Figure 2

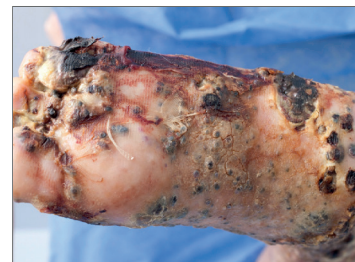

Figure 3

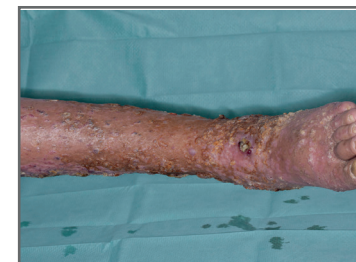

Figure 4

Results

Importantly, John found the dressing regimen to be comfortable and manageable, with improvements to the wounds evident within a matter of 2-3 weeks (fig.3). The amount of devitalised tissue had reduced, together with exudate levels and malodour; there was a noticeable reduction in the wound dimensions. As John's pain also reduced there was an improvement in his quality of life and he felt able to go out again for the first time in months. There were no further signs of infection throughout treatment with Flaminal®. John commented: "I feel that Flaminal® makes a big difference; first of all, it is painless upon application and no further pain is felt until the next dressing change, which I cannot say of previous dressings...I have seen the biggest and deepest wound on my feet, nearly healing in a two-month period" (fig.4).

Discussion

Any chronic malignant wound poses challenges for the health care professional. Healing the wound is not always a realistic wound management goal. Palliative wound care has been defined as: 'a holistic integrated approach to care that addresses symptom management and psychosocial wellbeing'.⁴ In order to properly manage malignant wounds, any malodour and exudate must be addressed, while concurrently focusing on managing the discomfort and isolation resulting from these wounds.⁵

Flaminal® (Flen Health), an Enzyme Alginogel® has a triple mode of action which avoided the need for multiple products. It has the capability to absorb excess exudate whilst remaining in a gelled state, promote debridement and control bioburden. The latter was vital in John's case as he was immunocompromised and it was important to reduce his risk of infection.

Conclusion

This case study demonstrates the effectiveness of Flaminal® in reducing pain and odour in complex and challenging malignant wounds, thus improving quality of life for the patient. Flaminal® has been shown to be antimicrobial, simple to use, capable of autolytically debriding a wound whilst absorbing exudate. It can be used throughout the wound trajectory and importantly in this case was acceptable to the patient providing him with some much-needed quality of life.