

# THE MANAGEMENT OF A PATIENT POST RHINECTOMY FOR SQUAMOUS CELL CARCINOMA

BARBARA FARRIMOND

<sup>1</sup>BSC HONS, HEAD & NECK ONCOLOGY, CLINICAL NURSE SPECIALIST, CENTRAL MANCHESTER UNIVERSITY HOSPITALS NHS FOUNDATION TRUST HOSPITAL, ENT DEPT PURPLE ZONE LEVEL 1, OXFORD ROAD M13 9WL

## Introduction

This case study describes the journey of Mr B, a 64-year-old gentleman, who presented to his doctor with a three month history of a lesion inside his nasal cavity. He was referred to the ENT oncology team on a two-week pathway. After a biopsy Mr B was given a diagnosis of squamous cell carcinoma (SCC) of the nasal vestibule. Malignancies of the nasal vestibule are rare and account for only 9% of all cancers of the nasal cavity; most of the tumours of the nasal vestibule are SCC (Fradis et al, 1993; Fornelli et al, 2000), arising predominantly on sun-damaged skin or long standing ulcers. Mr B underwent a complete rhinectomy, which is a radical resection of the entire nose and maxilla followed by complex reconstructive surgery required for such aggressive tumours.

Mr B who works in the wood industry and hence spent numerous years working outside exposed to UV rays, lives with his wife and son and has no significant medical history, enjoying a full and active life. He presented late to his GP as he had no external signs or symptoms but was aware of a lump within his nose.

## Method

On assessment during a home visit by the clinical nurse specialist in oncology two weeks post-surgery, Mr B had an area of necrotic and malodorous tissue over the entire nose area requiring debridement (Figure 1). The area was partially sharp debrided prior to utilising Flaminal® Hydro in the cavity to debride the remaining devitalised tissue and reduce the wound bioburden. In order to ameliorate excoriation of the skin from the exudate and prevent infiltration a gauze dressing was packed loosely into the nasal cavity. The dressing was changed three times per week for a total of three weeks. It was important that the area was debrided and kept free from infection so that prosthetic surgery could commence as soon as possible.

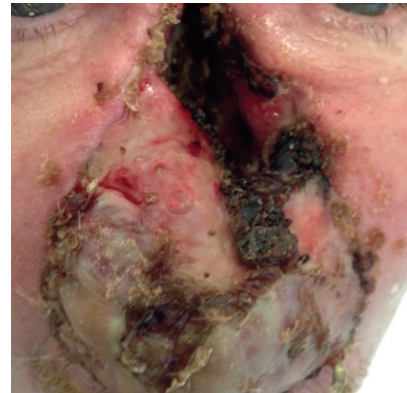


Figure 1.

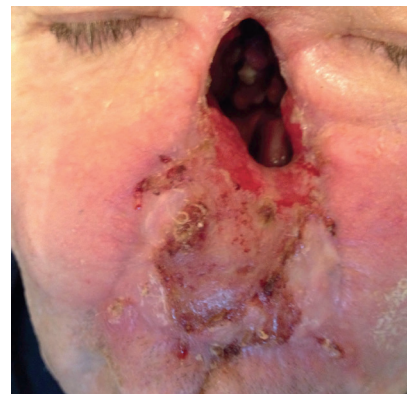

Figure 2.

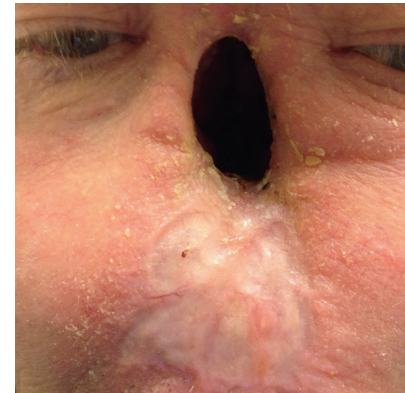

Figure 3.

## Results

Mr B tolerated the dressing regimen well and there was a marked improvement with the dressing regimen within one week (Figure 2); the area was fully debrided within a three week period and Mr B is awaiting further surgery to fit him with a prosthetic nose (Figure 3).

## Discussion

SCC is a non-melanoma skin cancer and the second most common type of skin cancer in the UK. More than 99,500 cases of non-melanoma skin cancer were registered in 2010 in the UK (Miller et al, 2010; Cancer Research UK, 2013). The UV component of sunlight, a carcinogen, is the major epidemiologic risk factor for SCC of the skin which accounts for about 20% of skin cancers. SCCs tend to affect the older generation and are more common in males than females with a history of smoking, betel quid chewing, alcohol, sun exposure (Davies, 2009) and human papilloma virus (<http://www.mouthcancerfoundation.org>).

The wound was dressed with Flaminal® Hydro (Flen Pharma), an antimicrobial enzyme alginate that combines the benefits of hydrogels and alginates with an antimicrobial to help reduce bacterial load and debride necrotic tissue through hydration and autolysis (Durante 2012).

A treatment plan was devised that would treat the wound and be acceptable to the patient. It was vital that time was taken to talk to Mr B and to constantly reassure him following such disfiguring and life changing surgery. He was provided with information and explanations enabling him to allow wound management to take place without becoming further agitated or distressed.

## Conclusion

Debridement and reduction in the bioburden of the wound were facilitated by Flaminal® Hydro in the management of this complex and challenging wound. The dressing regimen was found to be comfortable for Mr B and no analgesia was necessary during dressing change which can be a trigger for pain in chronic wounds (Meaume et al, 2004). Speedy debridement and control of bioburden meant that prosthetic surgery could commence as soon as possible.

## References

- Cancer Research UK (2013) Key Facts on Skin Cancer. Available: <http://info.cancerresearchuk.org/cancerstats/types/skin/> Accessed 29 July 2013
- Davies A (2009) The effective management of squamous cell carcinoma British Journal of Nursing Vol 18, No 9: 539-543
- Durante CM (2012) An open label non-comparative case series on the efficacy of an enzyme alginate. J Wound Care 21(1):22-28.
- Fornelli RA, Fedok FG, Wilson EP, Rodman SM (2000) Squamous cell carcinoma of the anterior nasal cavity: a dual institution review. Otolaryngeal Head Neck Surg 123: 207-10
- Fradis M, Posohin L, Gertner R, Sabo E (1993) Squamous cell carcinoma of the nasal septum mucosa. Ear Nose Throat J 72:217-21
- Meaume S, Telom L, Lazareth I et al (2004) The importance of pain reduction through dressing selection in routine wound management: the MAPP study. Journal of Wound Care 13 (10): 409-13
- Miller SJ, Alam M, Anderson J et al (2010) Basal cell and squamous cell skin cancers. J Natl Compr Canc Netw 8(8): 836-64